

The RUSH Exam

CHEAT SHEET



Rapid Ultrasonography for Shock and Hypotension

#1

Heart

PLAX: Ejection Fraction.
Sub-xiphoid: Effusion.
4 chamber: RV dilation.

#2

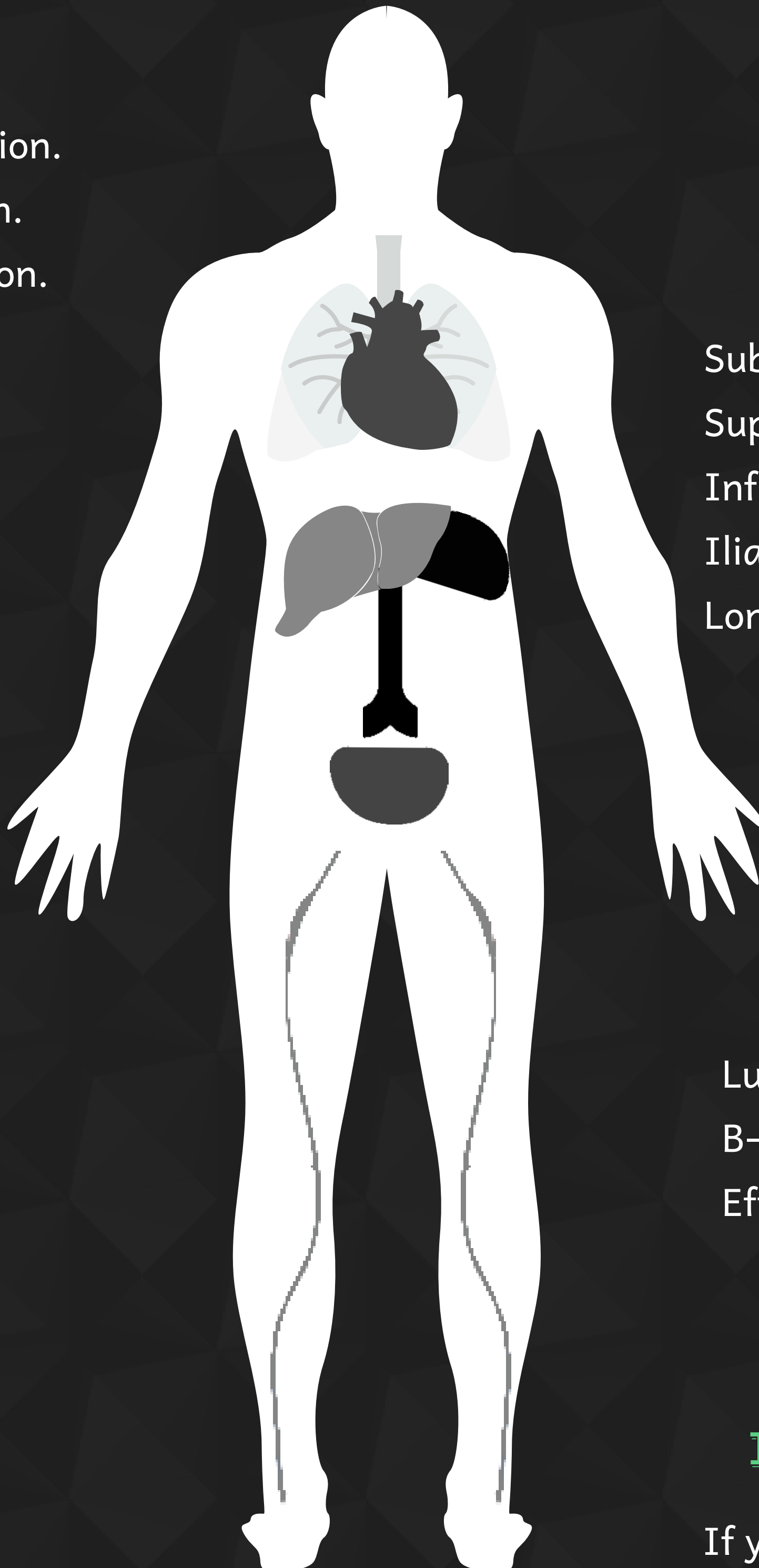
IVC

Narrow or wide?
Collapsible?

#3

Morrison

The "Fast" views.



#4

Aorta

Sub-xiphoid.
Suprarenal.
Infrarenal.
Iliac Bifurcation.
Longitudinal.

#5

Pulmonary

Lung Sliding.
B-lines.
Effusions.

#6

Bonus!

If you see RV dilation,
consider a DVT study to
clinch the dx!



@zaidaltawil



@BostonCityEM